

## Dopa Responsive Slow Orthostatic Tremor in Parkinson's Disease

Suk Yoon Lee  
Eun Joo Chung  
Yeo Jung Kim  
Sang Jin Kim

Department of Neurology,  
Inje University College of Medicine,  
Busan, Korea

Slow orthostatic tremor (OT) occurred to longer and lower frequency regular rhythmic bursts in leg muscle upon standing. The slow OT was often able to clinically confused with orthostatic myoclonus. We described a Parkinson's disease patient with levodopa responsive slow OT. She showed abnormal movements of more regular rhythms and stable frequency on both legs on standing. These symptoms were aggravated at off state and improved by increasing levodopa. **Journal of Movement Disorders 2011;4:82-84**

**Key Words:** Slow orthostatic tremor, Parkinson's disease.

Orthostatic tremor (OT) was characterized by unsteadiness on standing and improvement on sitting or walking.<sup>1</sup> Recently, OT has been reported to elderly patients with Parkinson's disease (PD).<sup>2-5</sup> Two types of OT were known to in PD which one is a slow OT (4-6 Hz), improved by levodopa,<sup>3,6,7</sup> and the other is a fast OT, mimicking primary OT (13-18 Hz).<sup>2,4,6,8</sup>

Myoclonus on upright posture was referred to orthostatic myoclonus (OM),<sup>9</sup> and OM could make clinically be confused OT in standing position. Thus, electromyography (EMG) recording was actually helping to differentiate between OM and OT.

We described a PD patient with orthostatism. Electrophysiologic recordings were much closed to slow OT rather than those of OM. In addition, her symptom showed good response of levodopa treatment and was gradually relieved. Therefore, we diagnosed as a PD patient complicated with slow OT.

### Case

A 81-year-old woman, who had been diagnosed as PD from 6 years ago, visited to our hospital because of unsteadiness of gait and postural instability. Her caregiver noted that her standing tremor at the lower limbs had been insidiously developed before 15 days and aggravated from 3 days before. Fifteen days ago, she was able to be walking by cane. She was treated with ropinirole 6 mg/day, amantadine 100 mg/day and levodopa 300 mg/day. On neurologic examination, she showed advanced PD with Hoehn and Yahr stage III, which was more severe on the right side. Abnormal movements on both legs occurred with latency of 1 to 3 seconds after upright posture (see Video, segment 1), and tended to be relieved at sitting or lying down. These movements visually showed frequency of bursts between 4-6 Hz. She could not stand on a line and standing out in the floor without help.

None of any EMG bursts were observed on the both anterior tibialis (AT) and medial gastrocnemius (MG) as well as left biceps brachii and extensor digitorum communis muscles at sitting posture. While burst activities were recorded on the vastus lateralis, AT and MG muscle pairs of both legs for standing (Figure 1). The bursts length was 50 to 120 ms and frequencies variously ranged from 4 to 9 Hz with generally regular rhythms. The bursts were weakly presented on state, and more deteriorated on off state. Brain magnetic resonance imaging represented somewhat cerebral atrophy and old periventricular ischemia. Routine blood tests including a complete blood count, electrolytes, glucose level, renal function tests, liver func-

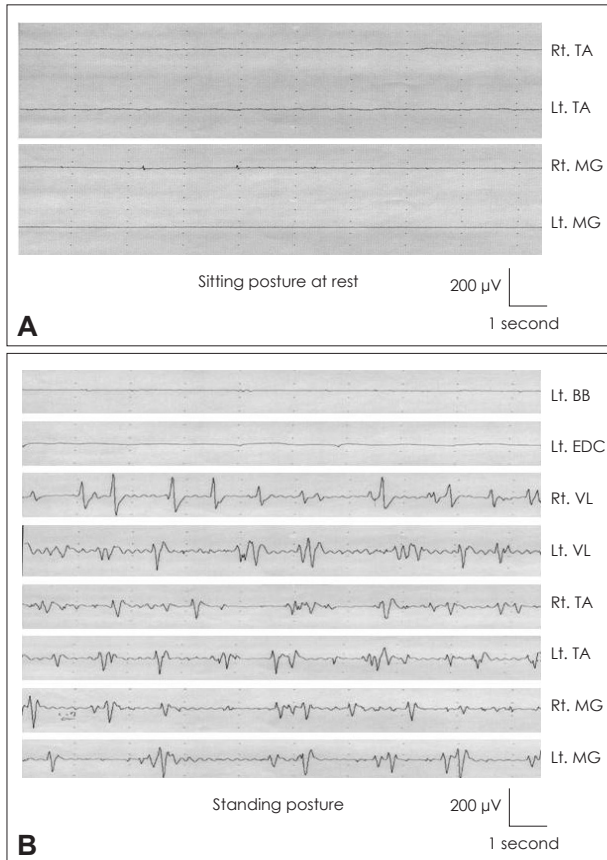
**Received** September 16, 2011

**Accepted** October 24, 2011

#### Corresponding author

Eun Joo Chung, MD  
Department of Neurology,  
Inje University College of Medicine,  
Busan Paik Hospital,  
633-165 Gaegeum-dong, Busanjin-gu,  
Busan 614-735, Korea  
**Tel** +82-51-890-6176  
**Fax** +82-51-895-6367  
**E-mail** strokerchung@yahoo.co.kr

· The authors have no financial conflicts of interest.



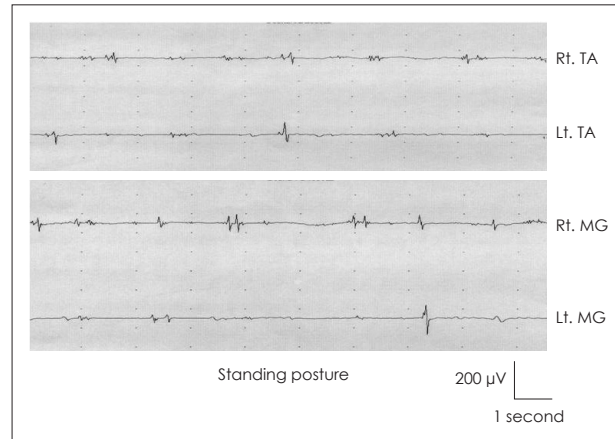
**Figure 1.** Surface electromyography (EMG) recordings of patient. First, there was no EMG bursts from both tibialis anterior (TA) and medial gastrocnemius (MG) muscles for sitting on a bed (A). Second, multichannel EMG recordings of a patient on standing showed brief irregular activities in the vastus lateralis, TA and MG muscles on both lower limbs in contrast to no discharge in the biceps brachii and extensor digitorum communis muscles on left upper limb (B).

tion tests, and thyroid function tests showed no significant abnormal findings.

When the levodopa was increased to 900 mg/day for 7 days by adding to existing treatment, standing movements in both legs were insidiously improved and jerky bursts of right leg on lying down were disappeared within 15 days. She could walk by herself for short distance (see Video, segment 2) and by cane for longer distance. She felt easier in standing still than before. Second followed EMG showed declined amplitude and frequencies of the burst movements (Figure 2).

## Discussion

Because of orthostatism and unsteadiness on standing posture, slow OT and OM is very difficult to be differentiated by visual analysis. Based on the surface electromyographic recordings in PD,<sup>6</sup> slow-OT has lower frequency (4-9 Hz), more regular and longer bursts length (80-120 ms) than that of OM (9-15 Hz, irregular rhythm, 30-70 ms, respectively). EMG find-



**Figure 2.** The electromyography recordings after increasing levodopa dosages were improved in both tibialis anterior and medial gastrocnemius muscles on standing.

ings of our patient are characterized by lower frequencies (4-9 Hz), rhythm of moderate regularity, and burst synchrony or asynchrony with long length (50-120 ms). This is immediately distinguished from typical fast OT and seems similar to rest-tremor frequency range of patient. Rest tremor is frequently presented in slow-OT patients in the off state, whereas it rarely occur to the fast-OT or OM groups.<sup>6</sup> Thus, orthostatism of our patient is near to slow OT, especially worsened on off state.

The improvement of orthostatism after increasing levodopa also raises possibility of slow OT in this patient. This agreed with previous results of slow OT in PD with good response to levodopa.<sup>3,6</sup> On the contrary, levodopa treatment might possibly be involved in the genesis of OM.<sup>6</sup> Levodopa-induced myoclonus is usually associated with OM which is thought as other types of levodopa-induced dyskinesia.<sup>6</sup> These considerations also suggest that orthostatism of our patient was not OM.

OT plus with other neurological features is able to be related with abnormal dopaminergic pathway at the level of basal ganglia.<sup>2</sup> And, this results in disinhibition of reticulospinal excitatory responses and causes an abnormal recruitment of spinal motor neurons.<sup>2</sup> Therefore, we suggested that slow OT in PD may be at the least of partly responsible for the abnormal dopaminergic pathology.

## Legends to the Video

Video Clip 1. The segment shows the involuntary jerks that predominantly involve the both legs. Myoclonus on both legs occurred with latency of 1 to 3 seconds after upright posture.

Video Clip 2. After 1 week of treatment with increasing levodopa, the patient showed significant improvement of orthostatic myoclonus.

## Acknowledgments

This work was supported by Grant from Inje University, 2009.

## REFERENCES

1. Deuschl G, Bain P, Brin M. Consensus statement of the Movement Disorder Society on Tremor. Ad Hoc Scientific Committee. *Mov Disord* 1998;13 Suppl 3:2-23.
2. Gerschlagel W, Münchau A, Katzenschlager R, Brown P, Rothwell JC, Quinn N, et al. Natural history and syndromic associations of orthostatic tremor: a review of 41 patients. *Mov Disord* 2004;19:788-795.
3. Thomas A, Bonanni L, Antonini A, Barone P, Onofrij M. Dopa-responsive pseudo-orthostatic tremor in parkinsonism. *Mov Disord* 2007;22:1652-1656.
4. Apartis E, Tison F, Arné P, Jedynak CP, Vidailhet M. Fast orthostatic tremor in Parkinson's disease mimicking primary orthostatic tremor. *Mov Disord* 2001;16:1133-1136.
5. Wills AJ, Brusa L, Wang HC, Brown P, Marsden CD. Levodopa may improve orthostatic tremor: case report and trial of treatment. *J Neurol Neurosurg Psychiatry* 1999;66:681-684.
6. Leu-Semenescu S, Roze E, Vidailhet M, Legrand AP, Trocetto JM, Cochen V, et al. Myoclonus or tremor in orthostatism: an under-recognized cause of unsteadiness in Parkinson's disease. *Mov Disord* 2007;22:2063-2069.
7. Kim JS, Lee MC. Leg tremor mimicking orthostatic tremor as an initial manifestation of Parkinson's disease. *Mov Disord* 1993;8:397-398.
8. Cristea RL, Goren H. Orthostatic tremor. *Arch Neurol* 1991;48:1119.
9. Glass GA, Ahlskog JE, Matsumoto JY. Orthostatic myoclonus: a contributor to gait decline in selected elderly. *Neurology* 2007;68:1826-1830.